

# Zygomatic implants: indications, techniques and outcomes, and the Zygomatic Success Code

CARLOS APARICIO, CAROLINA MANRESA, KAREN FRANCISCO, PEDRO CLAROS, JAVIER ALÁNDEZ, OSCAR GONZÁLEZ-MARTÍN & TOMAS ALBREKTSSON

In some patients, conventional implant treatment cannot be performed in the edentulous maxilla because of advanced bone resorption and/or the presence of extensive maxillary sinuses, leading to inadequate amounts of bone tissue for anchorage of the implants. For over three decades, bone grafting prior to, or simultaneously with, implant placement has become routine in oral rehabilitation. Various bone-augmentation techniques, such as sinus floor augmentation and onlay bone grafting, have been described with the common goal of increasing the volume of load-bearing bone (16, 28, 48, 50, 56, 57, 59, 77, 79–81, 83, 86, 91, 92).

The aims of this paper are: (i) to present an overview of the conventional grafting technique, the current gold standard in the treatment of extremely resorbed maxillae; (ii) to review an alternative treatment – the zygomatic implant; and (iii) to establish specific criteria to evaluate and report the success of a rehabilitation anchored on zygomatic implants.

## Conventional grafting for severely resorbed maxilla

For most indications, autogenous bone continues to be the gold standard for graft material. In addition to the risks and complications of the graft procedure itself, it also involves a donor site with associated surgical morbidity, additional operating time and extra costs. Systematic review articles (1, 38, 88) have emphasized that because of the heterogeneity among clinical trials, guidelines for clinical practice are difficult to define. However, one should be aware of the fact that the use of iliac crest bone grafts, for example,

in combination with immediate or delayed implant placement, has a failure rate of 10–30% (28, 57, 59, 83, 92).

Despite numerous publications, the effectiveness of sinus-grafting procedures remains controversial. Most of the literature describing these techniques lacks defined implant success and failure criteria or has not described the initial bone height and standardized radiographic follow up (48, 50, 79, 80, 86, 91).

In a systematic review of the lateral window technique, an estimated annual failure rate of 3.5%, translating into a 3-year implant survival of 90.1%, was found (77). The best results (98.3% implant survival after 3 years) were obtained with moderately rough surface implants. According to the authors, that systematic review had several shortcomings, as follows. First, the absence of appropriate randomized controlled trials, making it necessary to include papers with lower levels of evidence (e.g. prospective and retrospective cohort studies). Second, out of 48 reviewed studies, 65% did not report on dropouts. Third, it is known that the residual bone height significantly influences implant survival; however, many of the included studies failed to report the original residual bone height at the site of implant placement or graft failures. Finally, the studies included were conducted mainly in an institutional environment, such as universities or specialists' clinics.

Therefore, the long-term outcomes observed may not necessarily be generalized to the routine private practice. Different reviews of the transalveolar technique (56, 86) reported very similar results, with an estimated survival rate of 92.8% after 3 years of func-

tion. However, again, only 16% of the studies reported on dropouts. It was evident that the failure rate increased with reduced residual bone height and reduced implant length. A multicenter retrospective study (81) reported a survival rate of 96% when the residual bone height was 5 mm or more, compared with 85.7% when the residual bone height was 4 mm or less.

In a recent review, Esposito et al. (39) studied whether and when augmentation of the maxillary sinus is necessary and what the most effective augmentation techniques are. The results were based on 10 randomized controlled trials of different techniques and materials for augmenting the maxillary sinus and reported the outcome of implant success/failure at least to abutment connection. Unfortunately, the final evaluation had to be based on only a few small-sized trials with a short follow up. Therefore, the conclusions should be viewed as preliminary and judged to be at high risk of bias. To date, doubt still remains on the need and efficacy of sinus augmentation techniques before implant placement (39).

## The zygoma implant as an alternative treatment for the severely resorbed maxilla

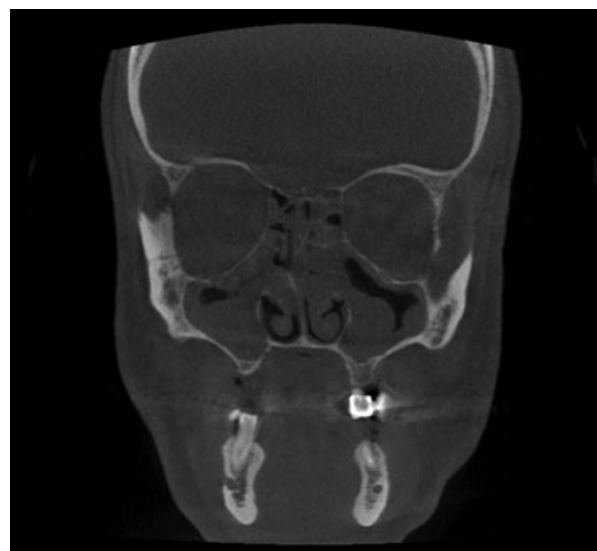
Efforts have been made to pursue alternatives to grafting procedures. The pterygomaxillary suture has been identified as an alternative site for implant placement (43, 47, 89). Others have suggested the use of tilted and/or short implants to avoid the need for sinus lift procedures (14). During the last two decades, the zygoma implant has proven to be an effective option in the management of the atrophic edentulous maxilla, as well as for maxillectomy defects (52). The Brånemark zygoma implant was introduced for the prosthetic rehabilitation of patients with extensive defects of the maxilla caused by tumor resections, trauma and congenital defects (8, 24, 51, 63). The bone of the zygomatic arch was used for anchorage of a long implant, which, together with ordinary implants, could be used as an anchor for epistheses, prostheses and/or obturators. The technique has enabled sufficient rehabilitation of these patients, providing restored function and improved esthetics, and has given many patients back a normal social life.

The use of multiple zygomatic implants (e.g. two to three in each side) to support a prosthesis was suggested by Bothur et al. (22). Despite numerous publications with positive long-term outcomes, there are

no randomized controlled trials comparing their clinical effectiveness with alternative means for rehabilitating patients with atrophic edentulous maxillae (41). Moreover, there are few published prospective long-term studies that endorse this technique (10, 18, 24). Currently, there are no clear, specific criteria that help the clinician to evaluate the success of a zygomatic-supported rehabilitation.

## Indications, contraindications and presurgical evaluation

After their initial clinical use in patients with neoplastic disease, the indication of zygomatic implants was expanded to completely edentulous patients with severe maxillary atrophy. Since then, the main indication for zygomatic implants – posterior maxillary support in patients who are completely edentulous with significant sinus pneumatization and severe posterior alveolar ridge resorption – has remained unchanged. For the most common indication, the zygomatic implants are combined with two to four anterior maxillary axial implants. Contraindications to the use of zygomatic implants include acute sinus infection, maxillary or zygoma pathology and patients unable to undergo implant surgery because of underlying uncontrolled or malignant systemic disease. Relative contraindications include chronic infectious sinusitis, the use of bisphosphonates and smoking more than 20 cigarettes a day. Any pathology of the maxillary



**Fig. 1.** Coronal image of a presurgical cone beam computed tomography scan shows bilateral occupation of both maxillary and ethmoidal sinuses. The osteomeatal complex is closed on both sides. Functional endoscopic sinus surgery was prescribed prior to zygomatic surgery.

sinus should preferably be treated before placement of the zygomatic implant (Fig. 1).

Once the clinical examination is complete, radiographic examination allows for further appropriate treatment planning of the zygomatic implant (49). Computed tomography is crucial for evaluation of the zygomatic implant site and the sinus status, as well as for the implant path. The amount of bone in the zygomatic arch and in the residual alveolar crest has to be explored. The angulation, expected emergence site and the relationship of the implant body to the maxillary sinus and the lateral wall are also considered. With the original technique, the path of the zygomatic implant was inside the maxillary sinus. The emergence of the head of the implant in the alveolar crest (typically in the palatal aspect of the second premolar region) is dependent on the spatial relationship of the zygomatic bone, the maxillary sinus and the alveolar crest. As discussed later, a new technique that includes the possibility of extra-sinus passage of the implant has been introduced, with promising results (Fig. 2).

According to Bedrossian et al. (18) the maxilla can be divided into three zones: zone 1, the premaxilla; zone 2, the premolar area; and zone 3, the molar area. The clinician should determine the availability of bone in all three zones. Cone beam computed tomography can be used to determine the amount of bone in these zones as well as in the zygomatic arch, in both horizontal and vertical dimensions. Moreover, any pathology in these areas, as well as in the maxillary sinuses, needs to be verified pre-operatively. In the presence of adequate bone in zones 1 and 2, the clinician can consider the use of four to six regular

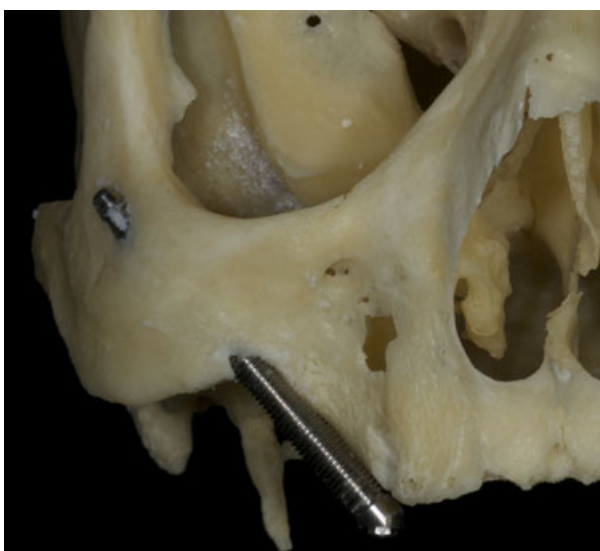

Fig. 2. Skull with a zygomatic implant placed following an extra-maxillary path.

implants, tilting the most distal one on each side to achieve good load distribution. As such, one can bypass the need for bone grafting. The anterior extent or position of the sinuses, as well as the slope of the anterior sinus walls, determine both the most posterior position of the distal implant as well as its angulation. This, unless the pterygoid region is used, ultimately impacts the most distal extent of the prosthesis (Table 1).

## General guidelines for zygomatic implants

The general guidelines for zygomatic implants (60) are as follows.

- Adequate bone in zone 1 for two to four axial implants and bilateral lack of bone in zones 2 and 3. Typically, two to four routine implants are distributed in the anterior maxilla plus one zygomatic implant on each premolar/molar side.
- Adequate bone in zone 1 and lack of bone in zones 2 and 3 on only one side. One single zygomatic implant is placed and routine implants are placed on the anterior maxilla and on the side opposite the zygomatic implant.
- Inadequate bone in zone 1 and adequate pristine bone in zones 2 and 3. An anterior zygomatic implant, together with posterior regular implants, can solve the problem.
- Lack of bone in all three zones of the maxilla. Four zygomatic implants can be used for the rehabilitation.
- Inadequate bone in zones 1, 2 or 3 in a partially edentulous patient. The placement of three implants to support a partial prosthesis is recommended; use of a zygomatic implant in partially edentulous patients requires more clinical validation before widespread use can be advocated.

**Table 1.** Treatment recommendations based on the presence of bone in the different zones of the maxilla (Bedrossian (18))

Presence of bone	Surgical approach
Zones I, II and III	Traditional (axial) implants
Zones I and II	Four regular implants (tilted)
Zone I only	Zygomatic implants plus two or four regular implants
Insufficient bone	Four zygomatic implants

- A rescue solution for patients in whom either regular implants and/or the maxillary bone-augmentation procedure have failed.

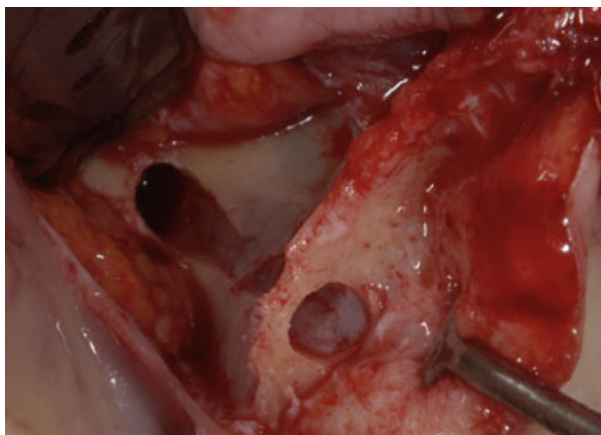
## Regional anatomy

With conventional dental implants, initial implant stability derives from mechanical retention between the implant surface and the bone tissue. This concept is also important when using zygomatic implants. The quantity and the quality of zygomatic bone were studied by Nkenke et al. (68); they concluded that the trabecular bone of the zygomatic arch was not favorable for implant placement and suggested that the success seen with zygomatic implants is probably a result of the engagement of four cortices (the lingual cortex of the maxillary alveolus, the cortical floor of the maxillary sinus at the crestal portion of the implant and the zygomatic bone cortices at the apex).

Corvello et al. (29) evaluated the length of the holes drilled in the zygomatic bone of 18 dry adult skulls during the placement of zygomatic implants using the original Brånemark and the exteriorized (extra-sinus) protocols. The exteriorized technique produced significantly longer drilling holes than the Brånemark technique, suggesting that the exteriorized technique may provide higher initial mechanical stability (Figs 2 and 3).

## Implant designs

The original Brånemark customized zygoma fixture was designed to be inserted from the palatal aspect of the resorbed maxilla in the region of the second pre-



**Fig. 3.** Clinical photograph illustrating the osteotomy in a zygomatic anatomy-guided approach type 3. Maximal use of the available bone is at hand. The palate has been respected, making a sinus complication more improbable.

molar, through the maxillary sinus into the compact bone of the zygoma. Initially it had the characteristics of a regular implant but with increased length and diameter. It was a self-tapping titanium implant with a machined surface and available in lengths of 30–52.5 mm (8, 24). The threaded apical part had a diameter of 4 mm and the crestal part had a diameter of 4.5 mm. The implant head was provided with an inner thread for connection of standard abutments. Later on, the implant head was angulated to 45° (24). In today's fixture the surface has evolved to a moderately rough oxidized threaded surface and the head includes an implant driver screw that remains inside the implant, offering an inner thread for the connection of special 'zygomatic' abutments.

Currently, zygomatic implants are commercially available from at least three different companies that offer implants with an oxidized rough surface, a smooth mid-implant body, a wider neck at the alveolar crest and a 55° angulation of the implant head.

## Surgical technique

### Anesthesia

According to the original protocol, surgery was carried out under general anesthesia with nasal intubation. A sealing throat pack and a gastric tube were used in each patient. Afterwards, local anesthetic was infiltrated with injections of lidocaine with epinephrine (1:50.000 to block the superior alveolar nerves (posterior, middle and anterior) and the palatal nerves (posterior and nasopalatal). The epinephrine helped to create a regional haemostasis. Hospital-based surgery was strongly recommended for those patients.

Recently, the protocol has been simplified with the use of local anesthesia and oral or intravenous sedation (14). This procedure is recommended if the surgeon is experienced and the procedure is expected to last for <1.5 h. The local anesthetic procedure includes the simultaneous use of four different local anesthetic approaches, as follows:

- Normal infiltration anesthesia (1:50.000 epinephrine) in the buccal sulcus from the central incisor to the third molar tooth using lidocaine with 1:50.000 epinephrine (about 3.6 ml) and block of the posterior superior alveolar nerve about 1 cm palatal to the bone crest.
- Infra-orbital nerve block by an oral approach using lidocaine (1:50.000 epinephrine) or felypressine with about 1.8 ml of prilocaine.

- Block of the sphenopalatine ganglion through the greater palatine foramen using lidocaine (1:50.000 epinephrine) or felypressine with about 1.8 ml of prilocaine.
- Infiltration anesthesia around the zygoma area through the skin using about 3.6 ml of lidocaine (1:50.000 epinephrine).

In the authors' experience, the procedure is well tolerated by the patient, and surgery is facilitated by working on a conscious patient (14).

## The original technique

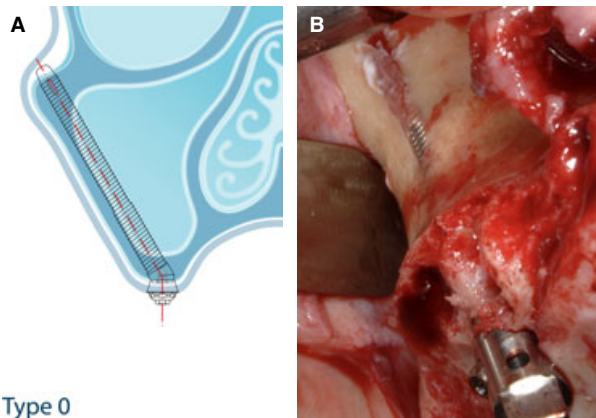
After an initial period during which a vestibular Lefort II type incision is used, the current protocol attempts to expose the area via a mid-crestal incision and vertical releasing incisions along the posterior part of the infra-zygomatic crest and anterior to the surgical site. The vertical ridge/ anterior border of the zygomatic arch is always identified. A second landmark is the lateral orbital border, as interference with the orbita must be avoided. Subsequently, a mucoperiosteal flap is raised, exposing the central/posterior part of the zygomatic complex, the lateral wall of the maxillary sinus and the alveolar crest. A retractor is positioned for visibility and to protect the soft tissues. An indicator is used to determine the drilling direction and the starting point at the crest, usually the second premolar/first molar region. A bone window, around 10 mm wide, is created at the lateral aspect of the maxillary sinus following the desired path of the zygomatic implant from the sinus floor to the top of the sinus cavity. The sinus membrane is carefully dissected, freed from the sinus walls and placed in the sinus cavity. A series of drills is used to penetrate the alveolar process and the zygomatic bone. The estimated length of the zygomatic implant is selected using a depth gauge. The self-tapping zygomatic implant is placed with the aid of a motor or manually, using an implant mount. Care should be taken not to enlarge the palatal hole during insertion, which is especially important in patients with thin alveolar/basal bone. If needed, bone particles harvested locally can be packed around the implant in an effort to diminish an eventual gap between the implant surface and the palatal bone. A cover screw is placed on the implant and the mucoperiosteal flap is closed. Abutment connection is usually made after a healing period of 6 months, using standard or straight/angulated multiunit Brånemark abutments.

## Modifications of the original protocol: the zygomatic anatomy-guided approach

In patients with pronounced buccal concavities on the lateral aspect of the maxillary sinus, the use of the original technique with an intra-sinus path results in excessive palatal emergence of the implant head. This commonly results in a bulky dental bridge at the palatal aspect, which sometimes leads to discomfort and problems with oral hygiene and speech (3, 17, 23, 42).

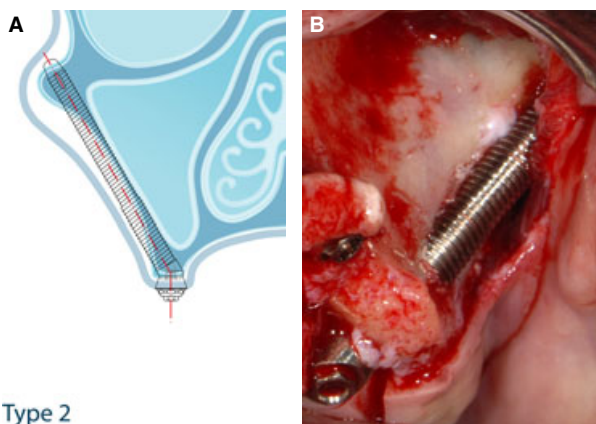
In order to use an anatomically and more prosthetically driven approach, the original technique has been modified by allowing an extra-sinus path for zygomatic implants (12, 14, 13, 23, 64, 74, 84). The authors have been working with a concept called the zygomatic anatomy-guided approach (ZAGA) (4, 5), a modification of the original zygomatic implant technique that focuses on interindividual anatomic differences. The preparation of the implant site is now guided by the anatomy of the area, and no initial window or slot is opened at the lateral wall of the maxillary sinus. Thus, depending on the relationship between the zygomatic buttress and the intra-oral starting point of the zygomatic implant, the path of the implant body will vary from being totally intra-sinus to being totally extra-sinus (Fig. 3). In other words, the new approach mentioned for the placement of the zygomatic implant is neither 'internal' nor 'external' to the sinus wall but, instead, promotes the placement of the zygomatic implant according to the anatomy of the patient.

Postoperative cone beam computed tomography images and clinical intrasurgery photographs of 200 sites corresponding to 100 of the 177 patients treated, between April 2005 and December 2010, with zygomatic implants using the referred anatomy-driven prosthetic approach (i.e. the zygomatic anatomy-guided approach) were reviewed by an independent investigator with regard to the anatomy and the pathway of the zygomatic implant body. Of special interest was the morphology of the lateral sinus wall, the residual alveolar crest and the zygomatic buttress. As a result, five basic skeletal forms of the zygomatic buttress-alveolar crest complex and subsequent implant pathways were identified. Accordingly, a classification system comprising five groups, namely ZAGA 0-IV, was proposed (4). It is believed that the proposed system is useful for classifying zygomatic implant patients for therapy planning and for scientific follow-up purposes (Figs 4-8). Placement of the long implant following the ZAGA principles optimizes support provided by the bone, even at the level of the maxillary wall, which is critical in a patient suffering from extreme



Type 0

**Fig. 4.** Schematic (A) and clinical (B) examples of a zygomatic anatomy-guided approach (ZAGA) type-0 path. The anterior maxillary wall is very flat. The first osteotomy is placed on the residual alveolar crest. The implant body reaches the zygoma bone following an intrasinusal path.



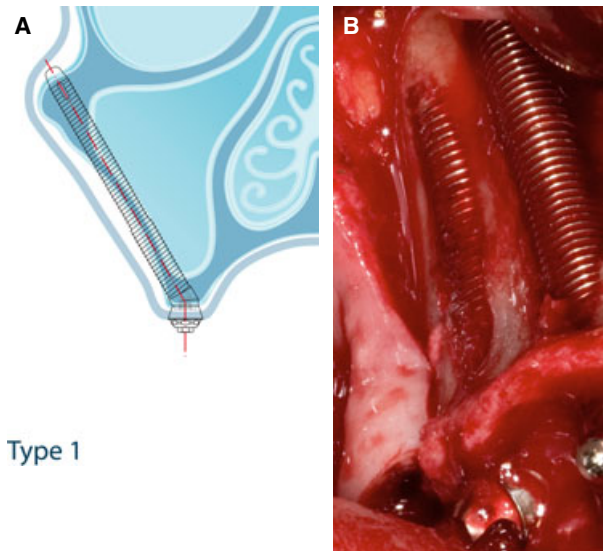
Type 2

**Fig. 6.** Schematic (A) and clinical (B) examples of a zygomatic anatomy-guided approach (ZAGA) type-2 path. In the presence of a more concave maxillary wall, ideal placement of the implant head forced most of the implant body to be placed extra-sinusally. However, no space was left between the implant surface and the anterior maxillary bone.

bone atrophy. The implant itself seals the wall osteotomy, which minimizes the risk of sinus contamination. Moreover, the clinician will be able to use the available crestal bone, allowing also for bone integration at the implant body and neck level in most ZAGA types.

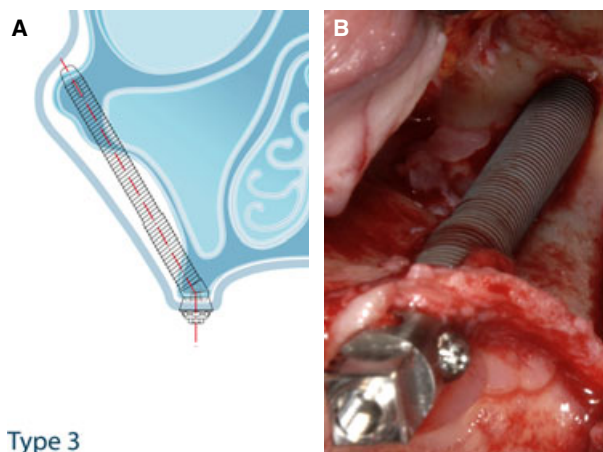
## Prosthetic procedure

The zygomatic implant has an increased tendency to bend under horizontal loads (30). This is related to two factors: the greatly increased length of these implants (30–52.5 mm) and the fact that in some circumstances there is limited or no bone support in the maxillary alveolar crest. Consequently, these implants have to be rigidly connected to stable conventional implants in the anterior maxilla. Based on clinical



Type 1

**Fig. 5.** Schematic (A) and clinical (B) examples of a zygomatic anatomy-guided approach (ZAGA) type-1 path (posterior implant). The desire to place the implant head in the correct prosthetic site, together with the presence of a slightly concave anterior maxillary wall, caused the implant osteotomy to perforate the maxillary wall. Regardless, most of the implant body remained inside the maxillary boundaries.

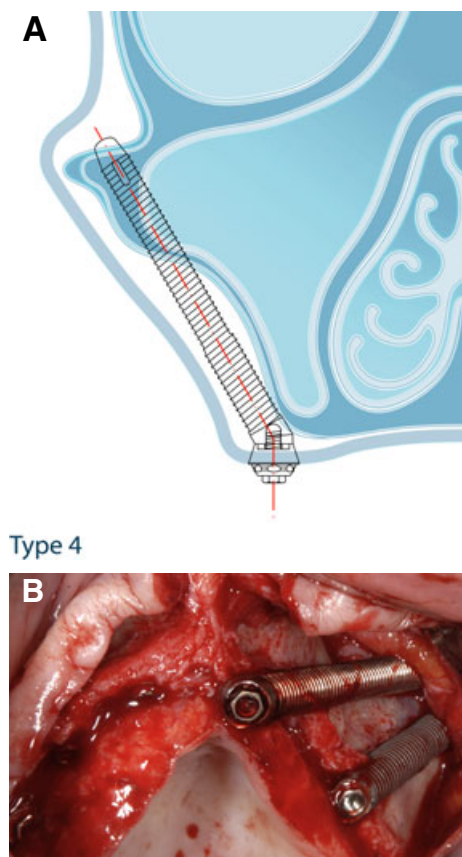


Type 3

**Fig. 7.** Schematic (A) and clinical (B) examples of a zygomatic anatomy-guided approach (ZAGA) type-3 path. As a result of a very concave maxilla, the first osteotomy performed from the palatal side of the alveolar crest went out buccally to the maxillary bone until it reached the zygoma in a more cranial position. The middle part of the implant does not touch the bone.

experience and biomechanical theoretical calculations, a full-arch restoration of the maxilla, supported by two zygomatic implants (one on each side), should be assisted by at least two stable regular implants in the anterior maxilla (26).

The prosthetic procedure follows conventional protocols. As the emergence of the zygomatic implant is often 10–15 mm medial to the ridge, the bridge



**Fig. 8.** Schematic (A) and clinical (B) examples of a zygomatic anatomy-guided approach (ZAGA) type-4 path. The atrophied maxilla presented both vertical and horizontal resorption. To place the implant head in an optimal location, while avoiding perforation of a very thin palate, the surgeon had to choose an extra-maxillary path.

should be designed to enable proper oral hygiene in the area. Originally, a two-stage procedure was recommended for the zygoma technique (24). However, over time, the original protocol has been replaced with immediate loading (11, 19, 27, 33, 34, 36). Several clinical reports have shown good outcomes following immediate/early loading of zygomatic implants in the totally edentulous maxilla (44, 45, 54, 69, 72, 87). For instance, Ostman et al. was able to establish a treatment concept for immediate / early loading of dental implants (71) and in a zygoma study (72) reported the loss of only one (0.8%) of 123 implants in 20 patients after 1 year. Bedrossian et al. (19) reported no losses of 28 zygomatic and 55 routine implants in 14 patients after more than 12 months. In another study, Davo et al. (33) lost none of 36 directly loaded zygomatic implants, but lost three of 68 conventional implants, after a follow-up period of 6–29 months. Although the available studies are short term, the findings show that immediate/early loading is a viable treatment modality also when zygomatic implants are included in the treatment. Moreover, it

is reasonable to believe that any negative effect from immediate/early loading *per se* should be seen soon after commencing loading and not after a prolonged period of time.

The provisional prosthesis is extremely important for patients treated with zygomatic implants. The goals for such prostheses are to provide acceptable esthetics as well as masticatory and speech function during the healing process, and also to explore the occlusal and esthetic position of the teeth and soft-tissue substitutes (19, 27, 33, 36). The routine option for both provisional and final prostheses is to develop a screw-retained structure that can easily be removed in the event of complications. For this purpose, the surgeon must analyze the type of resorption in relation to the opposite dentition and provide an implant head with an adequate abutment type in length and angulation. The angulation of the abutment will be critical, not only for positioning the screw emergence on the palatal/occlusal surfaces but also for determining the final thickness of the prosthesis. As stated in our previous work (6, 7), the construction of the prosthesis starts at surgery. In fact, during implant placement the surgeon must provide the correct implant inclination in relation to the antagonist dentition. At present, the head of the zygomatic implant can be positioned more accurately by observing the screw locking the implant mount to the implant. The screw position duplicates the future abutment screw position exactly.

## Reported zygomatic implant outcomes

In a review of English-language scientific journals (14), 32 studies presenting clinical outcomes with a zygomatic implant were found. The publications included 1031 patients and 2131 zygomatic implants with a follow-up period of 6 months to 12 years. In total, 42 implants were reported as failures, giving an overall survival rate of 98.1%. However, it should be noted that some studies, in part, covered the same patient groups and therefore the precise number of patients and implants is questionable. Nevertheless, the preliminary data show that the zygomatic implant technique is highly predictable and results in good clinical outcomes. In comparison, an additional 3297 conventional implants, placed in the anterior region together with the zygomatic implants, had a survival rate of 95.9% (Table 2).

The Brånemark group started with the zygomatic implant concept. In an initial study, which reported

**Table 2.** Reported zygomatic implant outcomes

Study (reference)	Follow-up period	Patients (n)	Zygomatic implants	Failed zygomatic implants	Conventional implants	Failed conventional implants
Parel et al. (73)	1–12 years	27	65	0	?	?
Bedrossian et al. (21)	34 months	22	44	0	80	7
Vrielinck et al. (90)	<2 years	29	46	3	80	9
Boyes-Varley et al. (23)	6–30 months	45	77	0	?	?
Malevez et al. (62)	0.5–4 years	55	103	0	194	16
Branemark et al. (30)*	1–10 years	81	164	4	?	?
Hirsch et al. (53)	1 year	66	124	3	?	?
Branemark et al. (24)	5–10 years	28	52	3	106	29
Becktor et al. (17)	1–6 years	16	31	3	74	3
Penarrocha et al. (75)	1–1.5 years	5	10	0	16	0
Farzad et al. (42)	1.5–4 years	11	22	0	42	1
Ahlgren et al. (2)	1–4 years	13	25	0	46	0
Aparicio et al. (13)	0.5–5 years	69	131	0	304	2
Bedrossian et al. (19)	>12 months	14	28	0	55	0
Chow et al. (27)	10 months	5	10	0	20	0
Duarte et al. (36)†	6–30 months	12	48	2	0	–
Penarrocha et al. (74)	12–45 months	21	40	0	89	2
Davo et al. (33)	6–29 months	18	36	0	68	3
Mozzati et al. (67)	24 months	7	14	0	34	0
Pi-Urgell et al. (78)	1–72 months	54	101	4	221	15
Davó et al. (34)	12–42 months	42	81	0	140	4
Maló et al. (64)	6–18 months	29	67	1	57	0
Balshi et al. (15)	9–60 months	56	110	4	391	11
Davó (31)	60 months	21	45	1	109	11
Aparicio et al. (12)	6–8 months	20	41	0	87	0
Aparicio et al. (11)	7–38 months	25	47	0	127	0
Bedrossian (18)	84 months	36	74	2	98	0
Stiévenart et al. (85)†	6–40 months	20	80	3	0	–
Davó et al. (35)†	12 months	17	67	0	0	–
Migliorança et al. (66)	≥12 months	65	150	2	286	2
Aparicio et al. (10)	120 months	22	41	2	131	4
Aparicio et al. (9)	12–84 months	80	157	5	442	20
<b>Total</b>		<b>1031</b>	<b>2131</b>	<b>42</b>	<b>3297</b>	<b>139</b>

\*From Darle (30).

†Studies in which four zygomatic implants were placed for the treatment of extremely resorbed maxilla.

? No data available



on 27 patients with maxillary defects, none of 65 zygomatic implants placed were lost over the 1–12 years of follow up (25). In a more recent study from the same group, 5–10 years of data from 28 patients suffering just from maxillary atrophy treated with 52 zygomatic implants (machined surface) and 106 conventional implants were analyzed (24). Three of the 52 zygomatic implants were diagnosed as failures and were removed but not replaced. Of the 106 conventional implants originally placed during insertion of the zygomatic implant, 29 were lost (giving an implant survival rate of 73%). The failures occurred in 13 patients. Continuous fixed-prosthesis function throughout the study period was achieved in 23 (82%) of the 28 patients. By placing additional conventional implants, 27 (96%) of the 28 patients still had a prosthetic reconstruction supported by implants at the end of the study. Four patients had recurrent sinusitis during the follow up and were treated by improving the drainage from the sinuses through a new ostium inside the inferior turbinate. When evaluating the results of this pioneering study, the reader must bear in mind that bone grafting was deemed necessary in 17 (61%) patients to allow supporting conventional implants to be placed. Moreover, both zygomatic and regular implants were made of commercially pure titanium with a machined minimally rough surface.

Currently there are no appropriate randomized controlled trials showing the advantages of the zygoma technique in comparison with other procedures such as sinus augmentation or anterior grafting (1, 38, 48, 77).

Few long-term studies of zygomatic implants with a follow up of longer than 5 years (Table 2) have been published (9, 10, 17, 18, 24, 73, 78); all have a prospective or retrospective cohort design and were conducted mainly in institutions such as universities or specialists' clinics. Therefore, their long-term outcomes may not be generalized to dental services provided in routine private practice.

The percentages of sinus pathology in clinical studies with zygomatic implants are summarized in Tables 3 and 4, taking into account whether the procedure was developed in a two-stage protocol (Table 3) or immediate function (Table 4). Aparicio et al. (10) in a 10-year study, reported on 22 consecutive patients with zygomatic implants in a maintenance program. Patients were restored with a total of 172 implants (Nobel Biocare AB, Göteborg, Sweden) – 131 regular and 41 zygomatic (30–50 mm in length). Three regular implants failed (10 years' cumulative survival rate = 97.7%) and two zygomatic implants were removed at the 10 year follow-up visit (10 years'

cumulative survival rate = 95.1%). The mean  $\pm$  standard deviation of the head of the zygomatic implant relative to the center of the alveolar crest in the horizontal plane was  $5.12 \pm 2.38$  mm. All patients maintained functional prostheses. One patient fractured his framework twice. Loosening and fracturing of prosthetic screws or abutments occurred in seven and four patients, respectively. Seven patients fractured occlusal material (ceramic or resin). Four zygomatic implants in two patients were disconnected and five patients experienced acute sinusitis, 14–27 months postoperatively, and were treated with antibiotics. Another patient developed soft tissue infection and subsequent crestal bone loss and acute sinusitis 10 years postoperatively. It was in this patient that the zygomatic implants were cut and removed. Of the patients evaluated according to the Lund-Mackay score, 54.55% did not present opacification (Lund-Mackay = 0) in any sinus. Osteomeatal obstruction occurred in eight patients (two bilateral). Two (9.09%) were diagnosed with sinusitis (Task Force on Rhinosinusitis Criteria for the diagnosis of rhinosinusitis); 77% reported satisfaction levels above 81% and 32% reported the maximum satisfaction score of 100%.

Recently, Aparicio et al. (9) reported the results of a cohort group of 80 consecutive patients treated with zygomatic implants according to the surgical and prosthetic principles of the zygomatic anatomy-guided approach. All included patients had undergone at least 3 years of prosthetic follow up and had received pre- and postsurgical cone beam computed tomography scans. Implant installation was performed between 2004 and 2009. Four-hundred and forty-two regular implants and 157 zygomatic implants were placed. Four zygomatic implants failed in one patient, one implant fractured; and 20 regular implants were removed (cumulative survival rate = 95.5%). In the first case of zygomatic implant failure, the head of the implant fractured and could not be connected again. In the second case, rehabilitated with four zygomatic implants, screw loosening and subsequent mucositis developed along with a slight degree of mobility in all four implants, 2 years after placement (observed at the alveolar end of the zygomatic implant and not in the zygomatic anchorage). Three additional regular implants were placed as further anchorage for prostheses: two in the pterygoid region and one in the nasal spine. A new prosthesis had to be built but the original four zygomatic implants were still in place (cumulative survival rate = 98.9%). Three (3.8%) patients met the criteria for rhinosinusitis (i.e. a positive diagnosis of rhinosi-

**Table 3.** Sinus complications reported in different studies in which zygomatic implants were placed using the two-stage protocol

Two-stage protocol	Total number of patients	Follow-up period (months)	Survival rate of zygomatic implants, %	Sinusitis (%)
Bedrossian et al. (20)	22	34	100	0
Vrielink et al. (90)	29	12–24	92	2 (6.9)
Boyes-Varley et al. (23)	45	6–30	100	0
Malevez et al. (62)	55	6–48	100	5 (9)
Hirsch et al. (53)	76	12	98	3 (4)
Brånemark et al. (24)	28	72–108	94	4 (14.3)
Becktor et al. (17)	16	9–69 (average 46)	90.3	6 (26.6)
Zwahlen et al. (93)	18	6	94.4	1 (5.5)
Aparicio et al. (13)	69	6–60	100	3 (4.3)
Farzad et al. (42)	11	18–56	100	1 (9.1)
Ahlgren et al. (2)	13	12–56	100	0
Peñarrocha et al. (75)	21	12–60 (average 29)	100	2 (9.5)
Pi et al. (78)	54	1–72	96.04	0
Davo (31)	24	60	97.4	5 (20.8)
Stiévenart et al. (85)	10 (of 20)	40	96.25	1 (1.3)
Aparicio et al. (10)	22	120	97.71	2 (9.1)

nusitis based on task force rhinosinusitis for research outcomes and positive radiological Lund-Mackay assessment scores). The mean  $\pm$  standard deviation position of emergence of the head of the zygomatic implant in relation to the center of the alveolar crest in the horizontal plane was  $2.92 \pm 2.30$  mm. Fifty-five per cent of patients reported maximum satisfaction scores regarding their prosthesis (100% oral health impact profile for assessing health-related quality of life in edentulous adults score).

### Suggested criteria for success of zygoma implants: the Zygomatic Success Code

Rehabilitation using zygomatic implants, especially if those implants are extra-maxillary, is relatively new and different from treatment with regular implants as zygomatic implants differ in biomechanics and clinical treatment procedures. The extreme maxillary atrophy that indicates the use of zygomatic implants is associated with resorption changes in both alveolar and basal bone. Specifi-

cally, in zygomatic anatomy-guided approach type 4 surgery, the head of the implant is found buccally to the alveolar crest and there is no alveolar bone around its perimeter. This, together with the nonaxial placement of the zygomatic implants, makes it very common to encounter actual physical difficulty in placing radiographic intra-oral film properly in order to obtain standardized radiographs for measurement of marginal bone changes. The above makes it impossible to fulfill the success criteria used for regular implants placed on the residual crest. Currently, there are no clear criteria to describe possible complications derived from the sinus occupation/path of the zygomatic implant. Specific criteria for success/survival of zygomatic implants, different from those applied to rehabilitation with regular implants (40), are necessary. A Zygomatic Success Code describing specific criteria to score the success of a rehabilitation anchored on zygomatic implants is proposed (Table 5). The Zygomatic Success Code of a specific implant is represented by the outcome of the following variables: zygomatic implant stability (individually tested); associated sinus pathology; peri-implant soft-tissue

**Table 4.** Sinus complications reported in different studies in which zygomatic implants were placed using the immediate function protocol

Immediate function protocol	Total number of patients	Follow-up period (months)	Survival rate of zygomatic implants, %	Sinusitis (%)
Chow et al. (27)	5	6	100	0
Bedrossian et al. (19)	14	12–34	100	0
Davo et al. (33)	18	6–29	100	1 (5.5)
Duarte et al. (36)	12	6–30	97.9	0
Davó et al. (34)	42	12–42	100	1 (2.4)
Aparicio et al. (14)	20	6–48	100	0
Maló et al. (64)	29	6–18 (average 13)	98.5	4 (13.8)
Balshi et al. (15)	56	9–60	96.4	0
Mozzati et al. (67)	7	24	100	0
Davó et al. (34)	42	12–42 (average 20.5)	100	1 (2.4)
Bedrossian et al. (18)	36	84	97.2	3 (8.3)
Stiévenart et al. (85)	10 (of 20)	40	100	0
Davo et al. (35)	17	12	100	0
Migliorança et al. (66)	65	>12	98.7	0
Aparicio et al. (9)*	80	12–84 (average 48)	96.83	3 (3.75)

\*Established new criteria to report on rhinosinusitis diagnosis.

condition; and specific criteria for zygomatic prosthesis success (prostheses bucco lingual offset). Zygomatic implants can be scored by a code that includes four digits, each representing one specific criterion of success. A number is given depending on the condition of each criterion (e.g. 1/3/2/1). The success grade of the implant is determined by the worst condition of the four criteria (e.g. 1/3/2/1 would be classified as success grade III).

### Zygomatic implant stability

Owing to the specific biomechanics of extra-maxillary placed zygomatic implants, where little or no anchorage is attained at the head level, different degrees of implant stability can be found. Occasionally, when extra-sinusally placed implants are tested individually, slight mobility may be detected with no other associated pathological signs. That mobility comes from the elastic modulus of the anchoring zygomatic bone when bent by a remotely applied force. On the other hand, the movement must not be rotational, and it will disappear when implants are splinted together. A rotational movement should be considered as a sign of implant failure (Table 5).

### Diagnosis of associated sinus pathology: rhinosinusitis

Sinusitis in patients with zygomatic implants should be diagnosed in the same way as sinusitis in conventional patients, with some particularities. However, in the dental literature, there is no consensus on how to report a rhinosinusitis diagnosis. Rhinitis and sinusitis are among the most common medical conditions and are frequently associated. Therefore, many authors use the term rhinosinusitis (32, 37, 55, 61, 65). The vast majority of patients treated using zygomatic implants do not experience sinus pathology. It is not clear if sinusitis rates in patients with zygomatic implants are higher than in the general population. From the available data (32), the incidence of sinusitis is 6.6% for the classic two-stage protocol (Table 3), 2.8% for immediate function protocols (Table 4) and 5.5% if both protocols are considered together. However, there is a lack of standardized criteria for determining and reporting the sinus state. Given the current knowledge, the best way to avoid placing a zygomatic implant in patients with active sinusitis and to document this potential complication is to perform an exhaustive radiological (cone beam computed tomography including all sinuses) and clinical

**Table 5.** Zygomatic Success Code

Criteria	Condition I Success grade I	Condition II Success grade II	Condition III Success grade III	Condition IV Failure
Criterion A: zygomatic implant stability (individually tested)	No mobility No pain	Light clinical mobility No pain	Clear clinical mobility (no evidence of disintegration of the apical part of the implant or rotation) No pain	Clear clinical mobility (evidence of disintegration of the apical part of the implant) Rotation and/or pain
Criterion B: associated sinus pathology (Aparicio et al. (9))	Lanza and Kennedy test (-) Lund-Mackay score = 0	Lanza and Kennedy test (+) Lund-Mackay score = 0	Lanza and Kennedy test (-) Lund-Mackay score >0	Lanza and Kennedy test (+) Lund-Mackay score >0
Criterion C: peri-implant soft tissue condition	No recession	Light recession. Implant head is visible (yuxta-gingival) No exposed threads	Recession. Up to seven exposed threads	Recession. More than seven exposed threads
Criterion D: prosthetic offset*	0 mm ≤ D ≤ 6 mm -3 mm ≤ D ≤ 0 mm	6 mm < D ≤ 10 mm -4 mm ≤ D < -3 mm	10 mm < D ≤ 15 mm -5 mm ≤ D < -4 mm	D > 15 mm D < -5 mm

Description of the specific criteria (A, B, C and D) classifying zygomatic implants as successful (Grades I, II or III) or failed (Grade IV). The green color indicates success. The red color is considered as unacceptable (implant failure). Zygomatic implants are scored using a code consisting of four digits, each representing one specific criterion of success. A number is given depending on the condition of each criterion (for example, 1/3/2/1). The success grade of the implant is determined by the worst condition of the four criteria (i.e. 1/3/2/1 would be classified as success Grade III).

\*Prosthetic offset (D): distance from the center of the implant head to the center of the residual alveolar ridge. Positive values correspond to zygomatic implants placed palatally and negative values correspond to zygomatic implants placed buccally to the alveolar crest.

examination of all patients prior to the placement of a zygomatic implant. Patients with potential risk factors for the development of chronic rhinosinusitis should be identified, studied and, if necessary, treated by an otolaryngologist before implant placement (82).

#### Scoring a cone beam computed tomography scan

If chronic rhinosinusitis is suspected, a cone beam computed tomography scan of all sinuses must be performed (70). We suggest using the Lund-Mackay staging system, a validated scoring system recommended by the Task Force on Rhinosinusitis for research outcome (61). The radiological test includes six regions: anterior ethmoid; posterior ethmoid; maxillary; frontal; sphenoid; and osteomeatal complex. Each region is given a score of 0, 1 or 2 (Table 6). Any scan with a score of >0 would be considered an abnormal or 'positive' scan. In a previous study (9) Aparicio et al. compared the classical technique versus the ZAGA. The L-M score was statistically significantly lower for the ZAGA group (2.36 1 3.86 vs. 0.56 1 1.26,  $P = .042$ ).

#### Questionnaire for sinus reactions

A patient questionnaire developed, in 1997, by Lanza & Kennedy (58) to identify the presence of rhinosinusitis clinical symptoms, as specified by the Task Force

on Rhinosinusitis diagnostic clinical criteria (Table 7), must be presented to each patient. Each symptom question is answered 'yes' or 'no'. Diagnosis of sinusitis requires a 'yes' answer in two or more major criteria, in one major and two or more minor criteria, or purulence on nasal examination. Similarly, a statistically significant difference was reported by Aparicio and coworkers (9) ( $P = .047$ ) regarding the percentage of patients with no radiological signs or clinical symptoms of rhinosinusitis (L-M score zero and Lanza and Kennedy test negative) was observed between groups (54.55% for the classical technique vs. 76.25% with the ZAGA,  $P = .047$ ).

#### Peri-implant soft-tissue condition

One concern may be the long-term effect of having exposed threads towards the soft tissues at the lateral aspect of the zygomatic implants. Soft tissue dehiscences and their evolution must be reported in prospective studies. Photographs must be used to quantify the number of exposed threads (Table 5).

To understand why we are not using standard periodontal parameters, such as bleeding on probing or probing depth, the clinician should bear in mind that for different anatomic reasons, the zygomatic implant would be placed in different locations with respect to

**Table 6.** Lund-Mackay computed tomography staging system

		No abnormality	Partial opacification	Total opacification
Ant. ethmoid	R	0	1	2
	L	0	1	2
Post. ethmoid	R	0	1	2
	L	0	1	2
Maxillary	R	0	1	2
	L	0	1	2
Frontal	R	0	1	2
	L	0	1	2
Sphenoid	R	0	1	2
	L	0	1	2
		Not obstructed		obstructed
Osteomeatal complex	R		0	2
	L		0	2
Total score	–			

Ant., anterior; L, left; Post., posterior; R, right.

Lund-Mackay staging worksheet (61). Each region is scored as 0, 1 or 2. (0 represents no abnormality; 1 represents partial opacification; and 2 represents total opacification). The osteomeatal complex can only be scored as 0 or 2. The minimum possible score is 0 (negative computed tomography) and the maximum score is 24. A normal or 'negative' scan is defined as any scan with a L-M score of 0. Any scan with a score >0 was considered an abnormal or 'positive' scan. Total score is calculated by the addition of the scores of all regions plus the osteomeatal complex.

**Table 7.** Task force on Rhinosinusitis Criteria for the diagnosis of rhinosinusitis\*

Major criteria	Minor criteria
Facial pain or pressure	Headache
Facial congestion or fullness	Fever (all nonacute)
Nasal obstruction	Halitosis
Purulent discharge	Fatigue
Hyposmia or anosmia	Dental pain
Purulence on examination	Cough
Fever (acute only)	Otalgia or aural fullness

\*Diagnosis of rhinosinusitis requires: two or more major criteria; one major and two or more minor criteria; or purulence on nasal examination. From Lanza & Kennedy (58).

the residual crest, varying from a completely bone-surrounded implant head to just a buccal soft-tissue relationship. Moreover, when placing zygomatic implants following the original technique, the palatal bone thickness surrounding the implant head is frequently extremely poor or even nonexistent. In those cases, probing may cause disruption of the soft tissue sealing and cause oro-antral communication. Besides, an eventual probing would give different values depending on the intensity of the palatal curvature and whether it is located on the buccal side or the palatal abutment side.

## Specific criteria for zygomatic prosthesis success

A bulky dental bridge at the palatal aspect sometimes leads to discomfort, speech problems and problems with oral hygiene. For precise reporting on prosthesis success, anatomic measurements to assess the position of the head of the zygomatic implant with regard to the middle of the crest of the alveolar ridge in the horizontal axial dimension should be included. A positive value on this implant head position to the alveolar ridge relationship indicates a palatal position of the implant, whereas a negative value indicates a buccal emergency. An implant placed with no contact with the buccal bone at the head level will probably induce soft tissue dehiscence (Table 5).

## Summarizing remarks

The zygomatic implant was originally used in the rehabilitation of discontinuous maxillae to anchor an obturator prosthesis to the zygomatic bone. Despite unfavorable functional load direction and limited anatomy, clinical follow up indicated that zygomatic implants provided excellent anchorage for various prostheses. Based on these encouraging results, the zygomatic implant was later used as a treatment

option when only bone grafting procedures had failed. However, placement of zygomatic implants should be considered as a major surgical procedure and proper training is needed. As mentioned for the sinus floor elevation, the included zygoma studies were mainly conducted in an institutional environment, such as universities or specialists' clinics. Therefore, the long-term outcomes observed may not be generalized to dental services provided in routine private practice. Surgery is usually performed under general anesthesia, although recent research shows the possibility of performing zygomatic implant placement also under local anesthesia. Compared with major bone grafting, it is still a less invasive technique and can be used in cases where bone grafts cannot be harvested for some reason. In situations where bone grafting of the anterior maxilla is needed, intra-orally harvested grafts can be used before zygomatic and regular implants are installed.

An extra-sinusal approach to the placement of zygomatic implants is a modification of the standard technique reported in 2008 by Aparicio et al. (12) and subsequently in 2008 (14). A classification for the zygomatic patient has been proposed, establishing the relationship of the zygomatic buttress–alveolar crest complex to the various anatomy-guided zygomatic implant pathways (Figs 4–8) (4). This classification could help the clinician to refine the original technique for the placement of zygomatic implants by understanding the possibility of finding not only interindividual anatomic differences but also intra-individual ones. The possibility of placing zygomatic implants with part or all of their body out of the maxillary sinus should be linked to fewer sinus complications as less of the implant is inside the sinus and implants are placed more crestally, with reduced possibility of oro-antral communication (4). Moreover, when compared with the original technique, there is a clear improvement in the implant position for the prosthetic rehabilitation (9).

One concern of the technique may be the long-term effect of exposed threads toward the soft tissue at the lateral aspect of the zygomatic implants. Friberg & Jemt (46) were unable to observe any increased marginal bone loss or failure rate for machined implants with exposed threads at implant surgery compared with fully submerged implants followed up for 5 years. This is also the experience of the authors. Petruson (76) used sinuscopy of the maxillary sinuses of 14 patients with zygomatic implants, placed with no particular care regarding whether or not membrane disruption occurred, and found no signs of adverse reactions. As discussed by

Becktor et al. (17), it is likely that problems with sinusitis are related more to oro-antral communications than to exposed implant threads *per se*. The *in-vitro* study reported by Corvello et al. (29) showed that when the exteriorized technique was used, longer holes were required for zygomatic implant placement in the zygomatic bone than when using the original Brånemark technique, but no difference in implant length was found. Preference for one technique over the other should take into consideration the concavity formed by the ridge crest, maxillary sinus and region of implant insertion in the zygomatic bone.

Given the current knowledge (32) it seems that a low percentage of patients with zygomatic implants will develop rhinosinusitis. Interestingly, the rate is not very different from the sinusitis rate in the general population or the sinusitis rate associated with sinus grafts. As proposed by the authors (9), systematic parameters have to be used to report on sinus status. The diagnosis and treatment (by ear, nose and throat specialists) must follow the current recommendations for the treatment of rhinosinusitis in patients with no implants. In most cases, it seems that it will not be necessary to remove any osseointegrated zygomatic implants (18). The best way to avoid this potential complication might be to perform exhaustive radiological (computed tomography scan) and clinical examinations of all patients before the placement of a zygomatic implant; patients with potential risk factors for the development of chronic rhinosinusitis should be identified, studied and if necessary treated by staff of the Ear, Nose and Throat department before implant placement (32).

Finally, a Zygomatic Success Code, describing the specific criteria to score the success of a rehabilitation anchored on zygomatic implants, is proposed (Table 5).

## Conclusions

- Grafting to treat severely resorbed maxillae is currently the gold standard procedure, but failure rates of 10–30% have been reported in the literature.
- Zygomatic implants have, in many cases, shown improved clinical results compared with bone grafting and represent a possible new gold-standard procedure in compromised maxillary bone.
- Zygoma success criteria differ from those of ordinary implants because the proper evaluation of

crestal bone loss presents measurement problems. Instead, the current authors suggest the following: a cone beam computed tomography approach to evaluate whether sinuses are healthy; a clinical questionnaire where 'yes' and 'no' answers can be given; evaluation of soft tissue dehiscence on a four-point grading scale based on photographs obtained; and evaluation of prosthetic success based on final positioning of the zygomatic implant with respect to the center of the alveolar crest in the horizontal dimension.

## References

1. Aghaloo TL, Moy PK. Which hard tissue augmentation techniques are the most successful in furnishing bony support for implant placement? *Int J Oral Maxillofac Implants* 2007; **22**(Suppl.): 49–70.
2. Ahlgren F, Storksen K, Tornes K. A study of 25 zygomatic dental implants with 11 to 49 months follow-up after loading. *Int J Oral Maxillofac Implants* 2006; **21**: 421–425.
3. Al-Nawas B, Wegener J, Bender C, Wagner W. Critical soft tissue parameters of the zygomatic implant. *J Clin Periodontol* 2004; **31**: 497–500.
4. Aparicio C. A proposed classification for zygomatic implant patient based on the zygoma anatomy guided approach (ZAGA): a cross-sectional survey. *Eur J Oral Implantol* 2011; **4**: 269–275.
5. Aparicio C. The zygoma anatomy-guided approach (ZAGA). In: Aparicio C, editor. *Zygomatic implants: the anatomy guided approach*. Berlin: Ed. Quintessence, 2012: 113–135.
6. Aparicio C. ZAGA. The ABC to establish the implant trajectory. In: Aparicio C, editor. *Zygomatic implants: the anatomy guided approach*. Berlin: Ed. Quintessence, 2012: 137–162.
7. Aparicio A, Aparicio C. Prosthodontic aspects of the zygoma rehabilitation. In: Aparicio C, editor. *Zygomatic implants: the anatomy guided approach*. Berlin: Ed. Quintessence, 2012: 225–240.
8. Aparicio C, Brånemark PI, Keller EE, Olive J. Reconstruction of the premaxilla with autogenous iliac bone in combination with osseointegrated implants. *Int J Oral Maxillofac Implants* 1993; **8**: 61–67.
9. Aparicio C, Manresa C, Francisco K, Aparicio A, Nunes J, Claros P, Potau JM. Zygomatic implants placed using the zygomatic anatomy-guided approach versus the classical technique. A proposed system to report rhino-sinusitis diagnosis. *Clin Implant Dent Relat Res* 2013; 1–16. Doi: 10.1111/cid.12047.
10. Aparicio C, Manresa C, Ouazzani W, Francisco K, Claros P, Potau JM. The long-term use of zygomatic implants: a 10-year clinical and radiographic report. *Clin Implant Dent Relat Res* 2012. Doi: 10.1111/cid.12007.
11. Aparicio C, Ouazzani W, Aparicio A, Fortes V, Muela R, Pascual A, Codesal M, Barluenga N, Franch M. Immediate/early loading of zygomatic implants: clinical experiences after 2 to 5 years of follow-up. *Clin Implant Dent Relat Res* 2010; **12**(Suppl. 1): 77–82.
12. Aparicio C, Ouazzani W, Aparicio A, Fortes V, Muela R, Pascual A, Codesal M, Barluenga N, Manresa C, Franch M. Extra-sinus zygomatic implants: three year experience from a new surgical approach for patients with pronounced buccal concavities for the edentulous maxilla. *Clin Implant Dent Relat Res* 2010; **12**: 55–61.
13. Aparicio C, Ouazzani W, Garcia R, Arevalo X, Muela R, Fortes V. A prospective clinical study on titanium implants in the zygomatic arch for prosthetic rehabilitation of the atrophic edentulous maxilla with a follow-up of 6 months to 5 years. *Clin Implant Dent Relat Res* 2006; **8**: 114–122.
14. Aparicio C, Ouazzani W, Hatano N. The use of zygomatic implants for prosthetic rehabilitation of the severely resorbed maxilla. *Periodontol* 2000 2008; **47**: 162–171.
15. Balshi SF, Wolfinger GJ, Balshi TJ. A retrospective analysis of 110 zygomatic implants in a single-stage immediate loading protocol. *Int J Oral Maxillofac Implants* 2009; **24**: 335–341.
16. Becktor JP, Hallström H, Isaksson S, Sennerby L. The use of particulate bone grafts from the mandible for maxillary sinus floor augmentation before placement of surface-modified implants: results from bone grafting to delivery of the final fixed prosthesis. *J Oral Maxillofac Surg* 2008; **66**: 780–786.
17. Becktor JP, Isaksson S, Abrahamsson P, Sennerby L. Evaluation of 31 zygomatic implants and 74 regular dental implants used in 16 patients for prosthetic reconstruction of the atrophic maxilla with cross-arch fixed bridges. *Clin Implant Dent Relat Res* 2005; **7**: 159–165.
18. Bedrossian E. Rehabilitation of the edentulous maxilla with the zygoma concept: a 7-year prospective study. *Int J Oral Maxillofac Implants* 2010; **25**: 1213–1221.
19. Bedrossian E, Rangert B, Stumpel L, Indresano T. Immediate function with the zygomatic implant: a graftless solution for the patient with mild to advanced atrophy of the maxilla. *Int J Oral Maxillofac Implants* 2006; **21**: 937–942.
20. Bedrossian E, Stumpel L III, Beckely ML, Indresano T. The zygomatic implant: preliminary data on treatment of severely resorbed maxillae. A clinical report. *Int J Oral Maxillofac Implants* 2002; **17**: 861–865.
21. Bedrossian E, Stumpel LJ. Immediate stabilization at stage II of zygomatic implants: rationale and technique. *J Prosthet Dent* 2001; **86**: 10–14.
22. Bothur S, Jonsson G, Sandahl L. Modified technique using multiple zygomatic implants in reconstruction of the atrophic maxilla: a technical note. *Int J Oral Maxillofac Implants* 2003; **18**: 902–904.
23. Boyes-Varley JG, Howes DG, Lownie JF, Blackbeard GA. Surgical modifications to the Brånemark zygomaticus protocol in the treatment of the severely resorbed maxilla: a clinical report. *Int J Oral Maxillofac Implants* 2003; **18**: 232–237.
24. Brånemark PI, Grøndahl K, Ohnell O, Nilsson P, Petruson B, Svensson B, Engstrand P, Nannmark U. Zygoma fixture in the management of advanced atrophy of the maxilla: technique and long-term results. *Scand J Plast Reconstr Surg Hand Surg* 2004; **38**: 70–85.
25. Brånemark P-I, Grøndahl K, Worthington P. Appraisal of restored anatomy and function. In: Brånemark P-I, Grøndahl K, Worthington P, editors. *Osseointegration and autogenous bone grafts: reconstruction of the edentulous atrophic maxilla*. Berlin: Ed. Quintessence, 2001: 1–13.

26. Brunski John B. Biomechanical aspects of tilted regular and zygomatic implants. In: Aparicio C, editor. *The anatomy guided approach*. Berlin: Ed. Quintessence, 2012: : 25–45.
27. Chow J, Hui E, Lee PK, Li W. Zygomatic implants protocol for immediate occlusal loading: a preliminary report. *J Oral Maxillofac Surg* 2006; **64**: 804–811.
28. Collins TA, Brown GK, Johnson N, Massey JA, Nunn BD. Team management of atrophic edentulous with autogenous inlay, veneer, and split grafts and endosseous implants: case reports. *Quintessence Int* 1995; **26**: 79–93.
29. Corvello PC, Montagner A, Batista FC, Smidt R, Shinkai RS. Length of the drilling holes of zygomatic implants inserted with the standard technique. *J Craniomaxillofac Surg* 2011; **39**: 119–123.
30. Darle C. *Brånemark system, Nobel Biocare*, 2nd edn. Gothenburg, Sweden: Nobel Biocare AB, 2000.
31. Davo R. Zygomatic implants placed with a two-stage procedure: a 5-year retrospective study. *Eur J Oral Implantol* 2009; **2**: 115–124.
32. Davo R. Sinus reactions to zygomatic implants. In: Aparicio C, editor. *The anatomy guided approach*. Berlin: Ed. Quintessence, 2012: 59–76.
33. Davo C, Malevez C, Rojas J. Immediate function in the atrophic maxilla using zygoma implants: a preliminary study. *J Prosthet Dent* 2007; **97**: S44–S51.
34. Davó R, Malevez C, Rojas J, Rodríguez J, Regolf J. Clinical outcome of 42 patients treated with 81 immediately loaded zygomatic implants: a 12-to-42 month retrospective study. *Eur J Oral Implantol* 2008; **1**: 141–150.
35. Davo R, Pons O, Rojas J, Carpio E. Immediate function of four zygomatic implants: a 1-year report of a prospective study. *Eur J Oral Implantol* 2010; **3**: 323–334.
36. Duarte LR, Filho HN, Francischone CE, Peredo LG, Brånemark PI. The establishment of a protocol for the total rehabilitation of atrophic maxillae employing four zygomatic fixtures in an immediate loading system – a 30-month clinical and radiographic follow-up. *Clin Implant Dent Relat Res* 2007; **9**: 186–196.
37. Dykewicz MS, Hamilos DL. Rhinitis and sinusitis. *J Allergy Clin Immunol* 2010; **125**(Suppl. 2): 103–115.
38. Esposito M, Grusovin MG, Coulthard P, Worthington HV. The efficacy of various bone augmentation procedures for dental implants: a Cochrane systematic review of randomized controlled clinical trials. *Int J Oral Maxillofac Implants* 2006; **21**: 696–710.
39. Esposito M, Grusovin MG, Rees J, Karasoulos D, Felice P, Alissa R, Worthington HV, Coulthard P. Interventions for replacing missing teeth: augmentation procedures of the maxillary sinus. *Cochrane Database Syst Rev* 2010; (3): CD008397.
40. Esposito M, Hirsch JM, Lekholm U, Thomsen P. Biological factors contributing to failures of osseointegrated oral implants. (I). Success criteria and epidemiology. *Eur J Oral Sci* 1998; **106**: 527–551.
41. Esposito M, Worthington HV, Coulthard P. Interventions for replacing missing teeth: dental implants in zygomatic bone for the rehabilitation of the severely deficient edentulous maxilla. *Cochrane Database Syst Rev* 2005; (4): CD004151.
42. Farzad P, Andersson L, Gunnarsson S, Johansson B. Rehabilitation of severely resorbed maxillae with zygomatic implants: an evaluation of implant stability, tissue conditions, and patients opinion before and after treatment. *Int J Oral Maxillofac Implants* 2006; **21**: 399–404.
43. Fernandez Valerón J, Fernández Velázquez J. Placement of screw type implants in the pterigomaxillary pyramidal region: surgical procedure and preliminary results. *Int J Oral Maxillofac Implants* 1997; **12**: 814–819.
44. Fischer K, Stenberg T. Three-year data from a randomized, controlled study of early loading of single-stage dental implants supporting maxillary full-arch prostheses. *Int J Oral Maxillofac Implants* 2006; **21**: 245–252.
45. Fischer K, Stenberg T, Hedin M, Sennerby L. Five-year results from a randomized, controlled trial on early and delayed loading of implants supporting full-arch prosthesis in the edentulous maxilla. *Clin Oral Implants Res* 2008; **19**: 433–441.
46. Friberg B, Jemt T. Clinical experience of Ti-Unite implants: a 5-year cross-sectional, retrospective follow up study. *Clin Implant Dent Relat Res* 2010; **12**(Suppl. 1): 95–103.
47. Graves SL. Ten pterigoid plate implant: a solution for restoring the posterior maxilla. *Int J Periodontics Restorative Dent* 1994; **14**: 513–523.
48. Graziani F, Dono N, Needleman N, Gabriele M, Tonetti M. Comparison of implant survival following sinus floor augmentation procedures with implants placed in the pristine posterior maxillary bone: a systematic review. *Clin Oral Implants Res* 2004; **15**: 677–682.
49. Gröndahl HG, Gröndahl K, Lindfors N. Pre- and postoperative radiographic examinations of the zygoma implant site. In: Aparicio C, editor. *The anatomy guided approach*. Berlin: Ed. Quintessence, 2012: 47–56.
50. Hallman M, Hedin M, Sennerby L, Lundgren S. A prospective 1-year clinical and radiographic study of implants placed after maxillary sinus floor augmentation with bovine hydroxyapatite and autogenous bone. *J Oral Maxillofac Surg* 2002; **60**: 277–284.
51. Higuchi KW. The zygomaticus fixture: an alternative approach for implant anchorage in the posterior maxilla. *Ann R Australas Coll Dent Surg* 2000; **15**: 23–33.
52. Higuchi KW. Minimization in oral implant rehabilitation: a patient-centered ethics-based approach in zygomatic implants. In: Aparicio C, editor. *The anatomy guided approach*. Berlin: Ed. Quintessence, 2012: 1–6.
53. Hirsch JM, Ohnell LO, Henry PJ, Andreasson L, Brånemark PI, Chiapasco M, Gynther G, Finne K, Higuchi KW, Isaksson S, Kahnberg KE, Malevez C, Neukam FW, Sevett E, Urgell JP, Widmark G, Bolind P. A clinical evaluation of the Zygoma fixture: one year of follow-up at 16 clinics. *J Oral Maxillofac Surg* 2004; **62**(Suppl. 2): 22–29.
54. Horiuchi K, Uchida H, Yamamoto K, Sugimura M. Immediate loading of Brånemark system implants following placement in edentulous patients: a clinical report. *Int J Oral Maxillofac Implants* 2000; **15**: 824–830.
55. Hwang PH, Irwin SB, Griest SE, Caro JE, Nesbit GM. Radiologic correlates of symptom-based diagnostic criteria for chronic rhinosinusitis. *Otolaryngol Head Neck Surg* 2003; **128**: 489–496.
56. Jensen SS, Terheyden H. Bone augmentation procedures in localized defects in the alveolar ridge: clinical results with different bone grafts and bone-substitute materials. *Int J Oral Maxillofac Implants* 2009; **24**(Suppl.): 218–236.
57. Keller EE. Reconstruction of the severely atrophic edentulous mandible with endosseous implants: a 10 year



- longitudinal study. *J Oral Maxillofac Surg* 1995; **53**: 317–318.
58. Lanza DC, Kennedy DW. Adult rhinosinusitis defined. *Otolaryngol Head Neck Surg* 1997; **117**: s1–s7.
  59. Lekholm U, Zarb GA. Patient selection and preparation. In: Brånemark P-I, Zarb GA, Albrektsson T, editors. *Tissue integrated prostheses: osseointegration in clinical dentistry*. Chicago, IL: Quintessence, 1985: 199–209.
  60. Lesley D, Aparicio C. Indications and contra-indications for the use of the zygomatic implant. In: Aparicio C, editor. *The anatomy guided approach*. Berlin: Ed. Quintessence, 2012: 79–87.
  61. Lund VJ, Mackay IS. Staging in rhinosinusitis. *Rhinology* 1993; **31**: 183–184.
  62. Malevez C, Abarca M, Durdu F, Daelemans P. Clinical outcome of 103 consecutive zygomatic implants: a 6–48 months follow-up study. *Clin Oral Implants Res* 2004; **15**: 18–22.
  63. Malevez C, Daelemans P, Adrianssens P, Durdu F. Use of zygomatic implants to deal with resorbed posterior maxillae. *Periodontol 2000* 2003; **33**: 82–89.
  64. Maló P, Nobre Mde A, Lopes I. A new approach to rehabilitate the severely atrophic maxilla using extramaxillary anchored implants in immediate function: a pilot study. *J Prosthet Dent* 2008; **100**: 354–366.
  65. Meltzer EO, Hamilos DL, Hadley JA, Lanza DC, Marple DF, Nicklas RA, Bachert C, Baraniuk J, Baroody FM, Benninger MS, Brook I, Chowdhury BA, Druce HM, Durham S, Ferguson B, Gwaltney JM, Kaliner M, Kennedy DW, Lund V, Nacclerio R, Pawankar R, Piccirillo JF, Rohane P, Simon R, Slavin RG, Togias A, Wald ER, Zinreich SJ, American Academy of Allergy, Asthma and Immunology (AAAAI), American Academy of Otolaryngic Allergy (AAOA), American Academy of Otolaryngology–Head and Neck Surgery (AAO-HNS), American College of Allergy, Asthma and Immunology (ACAAI), American Rhinologic Society (ARS). Rhinosinusitis: establishing definitions for clinical research and patient care. *J Allergy Clin Immunol* 2004; **114**: 155–212.
  66. Migliorança RM, Coppedè A, Dias Rezende RC, de Mayo T. Restoration of the edentulous maxilla using extrasinus zygomatic implants combined with anterior conventional implants: a retrospective study. *Int J Oral Maxillofac Implants* 2011; **26**: 665–672.
  67. Mozzati M, Monfrin SB, Pedretti G, Schierano G, Bassi F. Immediate loading of maxillary fixed prostheses retained by zygomatic and conventional implants: 24-month preliminary data for a series of clinical case reports. *Int J Oral Maxillofac Implants* 2008; **23**: 308–314.
  68. Nkenke E, Hahn M, Lell M, Wiltfang J, Schultze-Mosgau S, Stech B, Radespiel Tröger M, Neukam FW. Anatomic site evaluation of the zygomatic bone for dental implant placement. *Clin Oral Implants Res* 2003; **14**: 72–79.
  69. Olsson M, Urde G, Andersen JB, Sennerby L. Early loading of maxillary fixed cross-arch dental prostheses supported by six or eight oxidized titanium implants: results after 1 year of loading, case series. *Clin Implant Dent Relat Res* 2003; **5**(Suppl. 1): 81–87.
  70. Oluwole M, Russell N, Tan L, Gardiner Q, White P. A comparison of computerized tomographic staging systems in chronic sinusitis. *Clin Otolaryngol* 1996; **21**: 91–95.
  71. Ostman PO. Immediate/early loading of dental implants. Clinical documentation and presentation of a treatment concept. *Periodontol 2000* 2008; **47**: 90–112.
  72. Ostman PO, Hellman M, Sennerby L. Direct implant loading in the edentulous maxilla using a bone density-adapted surgical protocol and primary implant stability criteria for inclusion. *Clin Implant Dent Relat Res* 2005; **7**(Suppl. 1): 60–69.
  73. Parel SM, Brånemark PI, Ohnell LO, Svensson B. Remote implant anchorage for the rehabilitation of maxillary defects. *J Prosthet Dent* 2001; **86**: 377–381.
  74. Peñarrocha M, Garcia B, Marti E, Boronat A. Rehabilitation of severely atrophic maxillae with fixed implant-supported prostheses using zygomatic implants placed using the sinus slot technique: clinical report on a series of 21 patients. *Int J Oral Maxillofac Implants* 2007; **22**: 645–650.
  75. Peñarrocha M, Uribe R, García B, Martí E. Zygomatic implants using the sinus slot technique: clinical report of a patient series. *Int J Oral Maxillofac Implants* 2005; **20**: 788–792.
  76. Petruson BE. Sinuscopy in patients with titanium implants in the nose and sinuses. *Scand J Plast Reconstr Surg Hand Surg* 2004; **38**: 86–93.
  77. Petruson BE, Tan WC, Zwahlen M, Lang NP. A systematic review of the success of sinus floor elevation and survival of implants inserted in combination with sinus floor elevation. *J Clin Periodontol* 2008; **35**(Suppl. 8): 216–240.
  78. Pi Urgell J, Revilla Gutiérrez V, Gay Escoda CG. Rehabilitation of atrophic maxilla: a review of 101 zygomatic implants. *Med Oral Patol Oral Cir Bucal* 2008; **13**: 363–370.
  79. Raghoobar GM, Timmenga NM, Vissink A. Maxillary bone grafting for insertion of endosseous implants: results after 12–124 months. *Clin Oral Implants Res* 2001; **12**: 279–286.
  80. Regev E, Smith RA, Perrot DH, Pogrel MA. Maxillary sinus complications related to endosseous implants. *Int J Oral Maxillofac Implants* 1995; **10**: 451–461.
  81. Rosen PS, Summers R, Mellado JR, Salkin LM, Shanaman RH, Marks MH, Fugazzotto PA. The bone-added osteotome sinus floor elevation technique: multicenter retrospective report of consecutively treated patients. *Int J Oral Maxillofac Implants* 1999; **14**: 853–858.
  82. Rosenfeld RM, Andes D, Bhattacharyya N, Cheung D, Eisenberg S, Ganiats TG, Gelzer A, Hamilos D, Haydon RC 3rd, Hudgins PA, Jones S, Krouse HJ, Lee LH, Mahoney MC, Marple BF, Mitchell CJ, Nathan R, Shiffman RN, Smith TL, Witsell DL. Clinical practice guideline: adult sinusitis. *Otolaryngol Head Neck Surg* 2007; **137**: S1–S31.
  83. Sjöstrom M, Sennerby L, Nilson H, Lundgren S. Reconstruction of the atrophic edentulous maxilla with free iliac crest grafts and implants: a 3-year report of a prospective clinical study. *Clin Implant Dent Relat Res* 2007; **9**: 46–59.
  84. Stella JP, Warner MR. Sinus slot technique for simplification and improved orientation of zygomatic dental implants. A technical note. *Int J Oral Maxillofac Implants* 2000; **15**: 889–893.
  85. Stiévenart M, Malevez C. Rehabilitation of totally atrophied maxilla by means of four zygomatic implants and fixed prosthesis: a 6-40-month follow-up. *Int J Oral Maxillofac Surg* 2010; **39**: 358–363.
  86. Tan WC, Lang NP, Zwahlen M, Pjetursson BE. A systematic review of the success of sinus floor elevation and survival of implants inserted in combination with sinus floor elevation. Part II: transalveolar technique. *J Clin Periodontol* 2008; **35**(Suppl. 8): 241–254.

87. Tarnow DP, Emtiaz S, Classi A. Immediate loading of threaded implants at stage 1 surgery in edentulous arches: ten consecutive case reports with 1- to 5-year data. *Int J Oral Maxillofac Implants* 1997; **12**: 319–324.
88. Tong DC, Rioux K, Drangsholt M, Bierne ORA. Review of survival rates for implants placed in grafted maxillary sinuses using meta-analysis. *Int J Oral Maxillofac Implants* 1998; **13**: 175–182.
89. Tulasne JF. Osseointegrated fixtures in the pterygoid region. In: Worthington P, Branemark PL, editors. *An advanced osseointegration surgery: applications in the maxillofacial region*. Chicago, IL: Quintessence, 1992: 182–188.
90. Vrielinck L, Politis C, Schepers S, Pauwels M, Naert I. Image based planning and clinical validation of zygoma and pterygoid implant placement in patients with severe bone atrophy using customized drill guides. Preliminary results from a prospective clinical follow-up study. *Int J Oral Maxillofac Surg* 2003; **32**: 7–14.
91. Wallace SS, Froum SJ. Effect of maxillary sinus augmentation on the survival endosseous dental implants. A systematic review. *Ann Periodontol* 2003; **8**: 328–343.
92. Widmark G, Andersson B, Carlsson GE, Ivanoff CJ, Lindvall AM. Rehabilitation of patients with severely resorbed maxillae by means of implants with or without bone grafts: a 1 year follow up study. *Int J Oral Maxillofac Implants* 1998; **13**: 474–482.
93. Zwahlen RA, Grätz KW, Oechslin CK, Studer SP. Survival rate of zygomatic implants in atrophic or partially resected maxillae prior to functional loading: a retrospective clinical report. *Int J Oral Maxillofac Implants* 2006; **21**: 413–420.

## **Abstract**

**The contents of this page will be published online only, as part of the html. It will not be published as part of the printed or PDF article.**

### **Abstract**

The zygoma implant has been an effective option in the management of the atrophic edentulous maxilla as well as for maxillectomy defects. Brånemark introduced the zygoma implant not only as a solution to obtain posterior maxillary anchorage but also to expedite the rehabilitation process. The zygoma implant is a therapeutic option that deserves consideration in the treatment-planting process. This paper reviews the indications for zygoma implants and the surgical and prosthetic techniques (including new developments) and also reports on the clinical outcome of the zygomatic anatomy-guided approach. An overview of conventional grafting procedures is also included. Finally, a Zygoma Success Code, describing specific criteria to score the success of rehabilitation anchored on zygomatic implants, is proposed.